



VETCT  
CONSULTANTS IN TELEMEDICINE

## IT'S YOUR CASE

Species: Canine

Breed: Chihuahua (Smooth Coat)

Sex: Female Neutered

Age: 7

### Clinical History:

7 yo FS Chihuahua. Normal this morning. When owner returned home she had vomited bile and blood 3-4 times. Kennelled when the owner is not home.

**Anatomic regions:** Abdomen

### Details of study and technical comments:

Three view abdominal and thoracic radiographs are available. The images are diagnostic.

### Diagnostic interpretation:

There are regions of decreased and increased serosal contrast. In the mid ventral abdomen, the margins of the caudal liver are effaced with the cranial aspects of the small intestine. On the left lateral view, the ventral boundary of the retroperitoneal space has improved definition. Multiple geometric gas opacities are distributed throughout the peritoneal space and several gas bubbles are noted outside of luminal structures (brown arrows).

The right hepatic silhouette has an increased volume and a vesiculated gas pattern (green arrows). This results in axial/leftward displacement of the pyloric antrum and caudal displacement of the gastric body.

The stomach, small intestine, colon, kidneys, spleen and urinary bladder are normal. The visible musculoskeletal structures are normal.



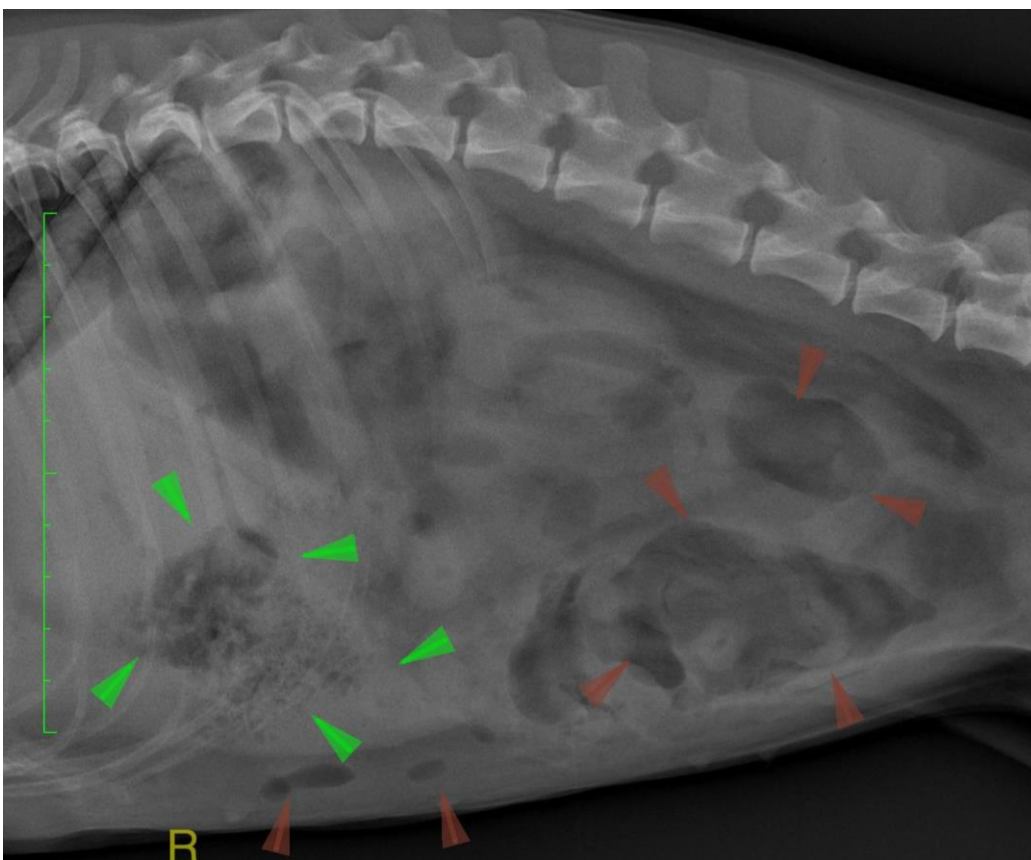
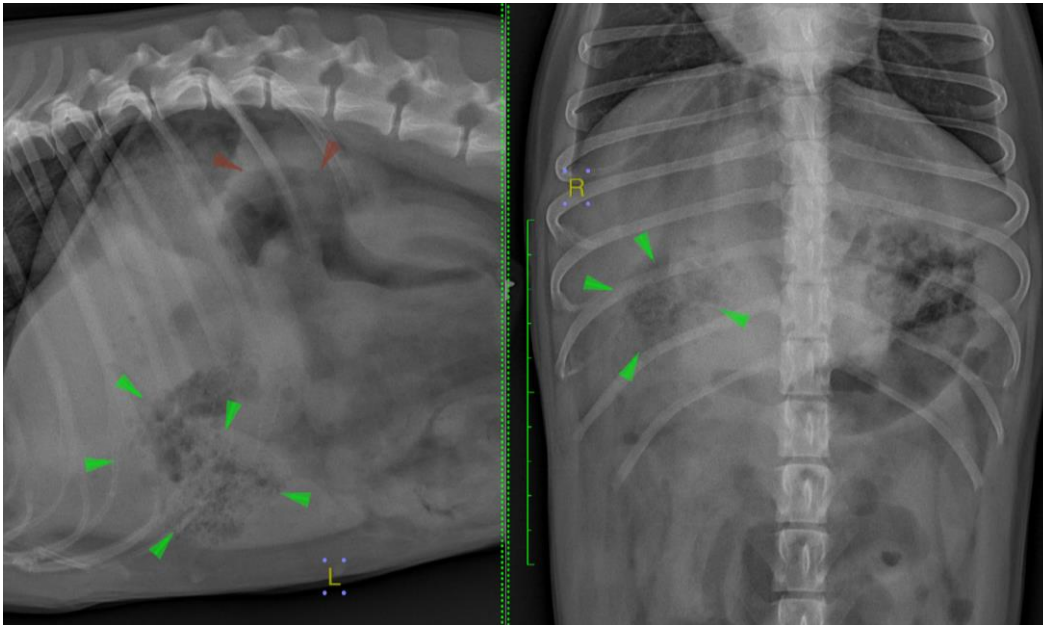
Reported by VetCT

t. +44 (0)1223 422251 www.vet-ct.com e. info@vet-ct.com

Co Number 6955449 Registered Office St John's Innovation Centre Cowley Road Cambridge CB4 0WS UK

ABN 24601862220 Registered Office in Australia Suite 11, 185-187 High Street Fremantle WA 6160 Australia

This report is based on the available history and radiographic interpretation only and not on a physical examination of the patient. It must therefore only be interpreted by a currently licensed and registered veterinary surgeon responsible for the care of this patient.



**Conclusions:**

1. Right hepatic cavitated gas filled mass (hepatic abscess vs. necrotic hepatic neoplasm- carcinoma)
2. Pneumoperitoneum and effusion. Primary consideration is given to septic peritonitis with or without rupture of the described hepatic pathology.



Reported by VetCT

t. +44 (0)1223 422251 www.vet-ct.com e. info@vet-ct.com

Co Number 6955449 Registered Office St John's Innovation Centre Cowley Road Cambridge CB4 0WS UK

ABN 24601862220 Registered Office in Australia Suite 11, 185-187 High Street Fremantle WA 6160 Australia

This report is based on the available history and radiographic interpretation only and not on a physical examination of the patient. It must therefore only be interpreted by a currently licensed and registered veterinary surgeon responsible for the care of this patient.

**Additional comments:**

Vesiculated gas within the hepatic silhouette is typical of necrotic tissue. This can occur in abscess formation or necrosis of a mass (when it has exceeded its blood supply). This tissue is often friable and minimal trauma/pressure can result in “laceration” of the liver and pneumoperitoneum. The most common hepatic neoplasm associated with hepatic cavitation is hepatocellular carcinoma.

In this case, the pathology within the liver is increasing the right liver volume. This produces a mass effect on the stomach. Generalized hepatomegaly results in caudal displacement of the gastric body while right sided hepatic enlargement, as seen here, can cause leftward displacement as well.

In general, cases with pneumoperitoneum have regions of increased contrast, these occur when peritoneal gas is juxtaposed to serosal margins. Pneumoperitoneum can be present from iatrogenic causes (surgery, abdominocentesis/cystocentesis) or pathology (rupture of a viscus structure). Viscus structures that are commonly implicated include the gastrointestinal tract, urinary tract or less commonly, hepatobiliary.

*This case has been tailored for academic use.*



**Reported by VetCT**

**t.** +44 (0)1223 422251 **www.vet-ct.com** **e.** info@vet-ct.com

Co Number 6955449 Registered Office St John's Innovation Centre Cowley Road Cambridge CB4 0WS UK  
ABN 24601862220 Registered Office in Australia Suite 11, 185-187 High Street Fremantle WA 6160 Australia

This report is based on the available history and radiographic interpretation only and not on a physical examination of the patient. It must therefore only be interpreted by a currently licensed and registered veterinary surgeon responsible for the care of this patient.