



VETCT
CONSULTANTS IN TELEMEDICINE

REPORTING SERVICE: CT

Report number: VETCT-99767

Report date: 27/10/2017

Referring Veterinarian: xxxx

Referring Practice: xxxx

Email address: xxxx

Owner: xxx Patient: xxx

Species: Equine Breed: N/A Sex: Male Neutered Age: 17 years, 9 months

Associated cases:

Clinical History:

Presented for convulsion. Partially blind left eye and cranial nerve deficit on the left side.

Questions to be answered:

Number of series / images: 4 / 2592

Series: [OS 1.0, TISSU MOU 1.0]

Study dated: 26/10/2017

Study received: 26/10/2017

Anatomic regions: Head

Details of study and technical comments: CT examination of the head. Images are presented in soft tissue and bone reconstruction. Images are of good diagnostic quality.



Reported by VetCT

t. +44 (0)1223 422251 www.vet-ct.com e. info@vet-ct.com

Co Number 6955449 Registered Office St John's Innovation Centre Cowley Road Cambridge CB4 0WS UK

ABN 24601862220 Registered Office in Australia Suite 11, 185-187 High Street Fremantle WA 6160 Australia

This report is based on the available history and radiographic interpretation only and not on a physical examination of the patient. It must therefore only be interpreted by a currently licensed and registered veterinary surgeon responsible for the care of this patient.

Diagnostic interpretation:

- There is a large heterogeneous mass in the lateral cerebral ventricles. The mass measures 5.3x2.8x6.2 cm in size, the largest portion of the mass is in the left ventricle. The mass is heterogeneous in density with a mean attenuation similar to the attenuation of the cerebral cortex (27-31 HU); there are hypoattenuating areas present within the mass, the largest of which is located in the caudal left portion of the mass with a mean attenuation of 16HU.
- The lateral ventricles are markedly enlarged; the left ventricle is almost completely filled by the mass while only the ventral portion of the right ventricle is. The cerebral cortex is reduced in thickness.
- There is evidence of caudal displacement of the pons caudal to the tentorium os cerebelli (subtentorial herniation); the cranial border of the cerebellum is distorted because of this compression.
- The optic nerve is normal.

Conclusions:

- Large extra-axial mass in the lateral ventricles causing obstruction of the CSF flow and secondary hydrocephalus. Ddx cholesterol granuloma most likely; other differentials include choroid plexus papilloma or choroid plexus tumour but these options are very rare in the horse.
- Subtentorial herniation secondary to mass effect.

Additional comments:

The mass identified in the ventricles is the likely cause for this horse clinical signs. The heterogeneous attenuation of the mass may be indicative of intra-lesional haemorrhage or possibly necrosis. Raised intracranial pressure likely the cause for the seizure activity; similarly, the reported blindness is likely secondary to compression of the visual cortex by the dilated ventricle.



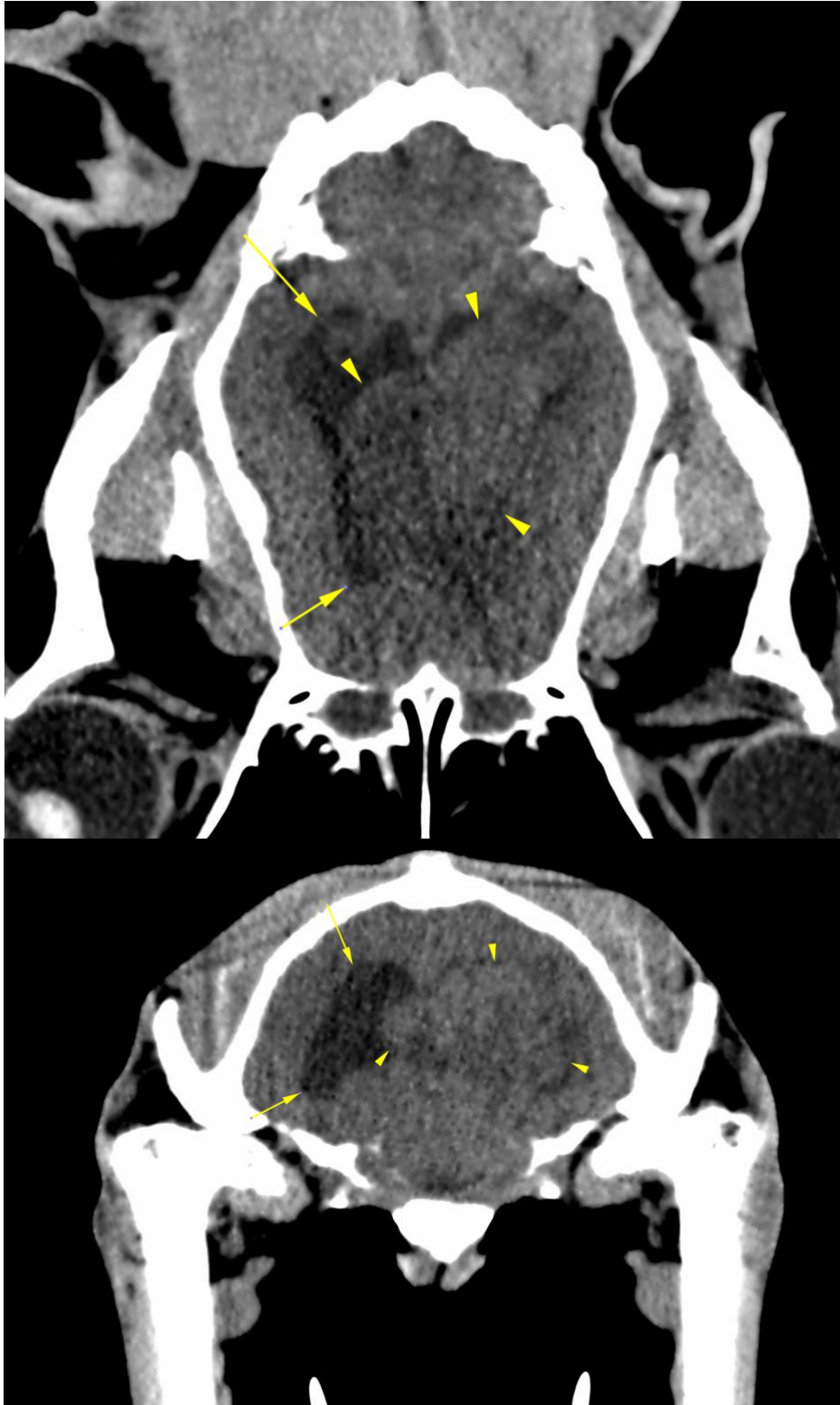
Reported by VetCT

t. +44 (0)1223 422251 www.vet-ct.com e. info@vet-ct.com

Co Number 6955449 Registered Office St John's Innovation Centre Cowley Road Cambridge CB4 0WS UK

ABN 24601862220 Registered Office in Australia Suite 11, 185-187 High Street Fremantle WA 6160 Australia

This report is based on the available history and radiographic interpretation only and not on a physical examination of the patient. It must therefore only be interpreted by a currently licensed and registered veterinary surgeon responsible for the care of this patient.



Dorsal and transverse image showing the large ventricular mass (arrowheads) and the dilated right ventricle.



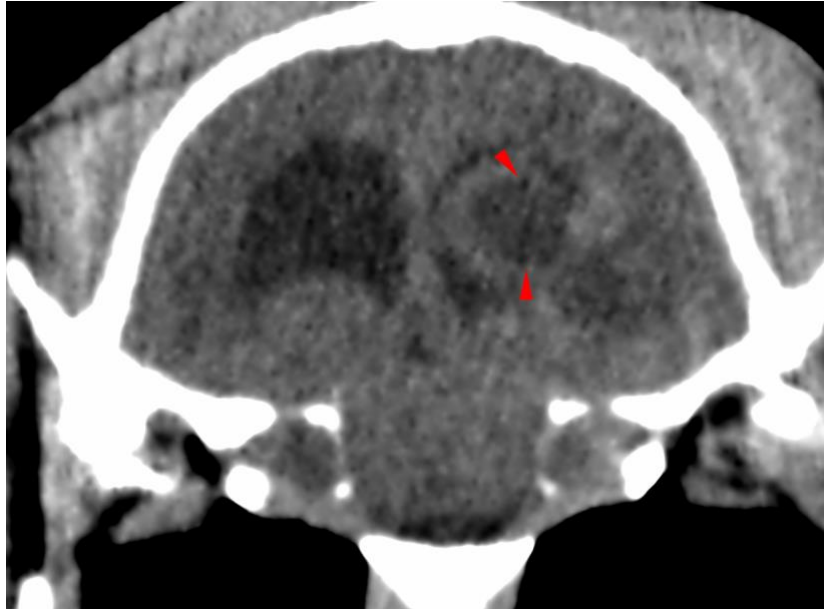
Reported by VetCT

t. +44 (0)1223 422251 www.vet-ct.com e. info@vet-ct.com

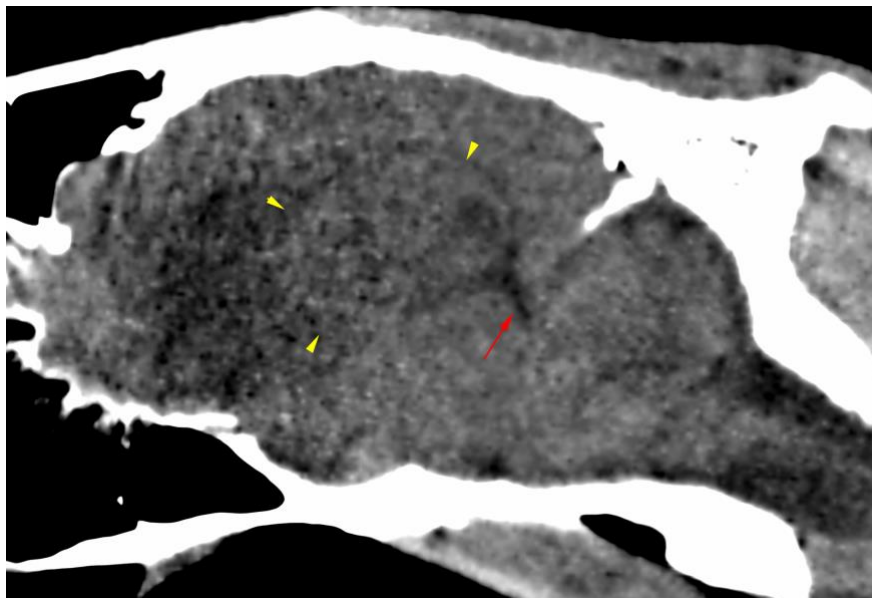
Co Number 6955449 Registered Office St John's Innovation Centre Cowley Road Cambridge CB4 0WS UK

ABN 24601862220 Registered Office in Australia Suite 11, 185-187 High Street Fremantle WA 6160 Australia

This report is based on the available history and radiographic interpretation only and not on a physical examination of the patient. It must therefore only be interpreted by a currently licensed and registered veterinary surgeon responsible for the care of this patient.



Transverse image of the caudal aspect of the cerebrum showing the hypodense area within the mass (arrowheads).



Mid sagittal reconstruction showing the mass (arrowheads) and the subtentorial herniation (arrow).

Reporting Radiologist:

xxxxx DVM, PhD, DipECVDI, MRCVS
European Specialist in Veterinary Diagnostic Imaging
RCVS Specialist in Veterinary Diagnostic Imaging

If you have any queries regarding this report then please "Add a comment" on the VetCT platform or contact info@vet-ct.com



Reported by VetCT

t. +44 (0)1223 422251 www.vet-ct.com e. info@vet-ct.com

Co Number 6955449 Registered Office St John's Innovation Centre Cowley Road Cambridge CB4 0WS UK

ABN 24601862220 Registered Office in Australia Suite 11, 185-187 High Street Fremantle WA 6160 Australia

This report is based on the available history and radiographic interpretation only and not on a physical examination of the patient. It must therefore only be interpreted by a currently licensed and registered veterinary surgeon responsible for the care of this patient.