

IT'S YOUR CASE

Species: Canine

Breed: Portuguese Water Dog

Sex: Female Entire Age: 3 years

Clinical History:

whelping - puppy count check, has whelped 5 live puppies so far

Diagnostic interpretation:

The caudal thoracic and the lumbar spine have a normal alignment. Both coxofemoral joints are within normal limits. The abdominal volume is increased. Four mineral dense skeletons are present with the abdomen. One is positioned with its head in the pelvic canal (4). There are no signs for degeneration or gas inclusions associated with the whelps. On the left, one of the puppies has the hindlimbs positioned cranially in a frog legged (but not extended cranially).

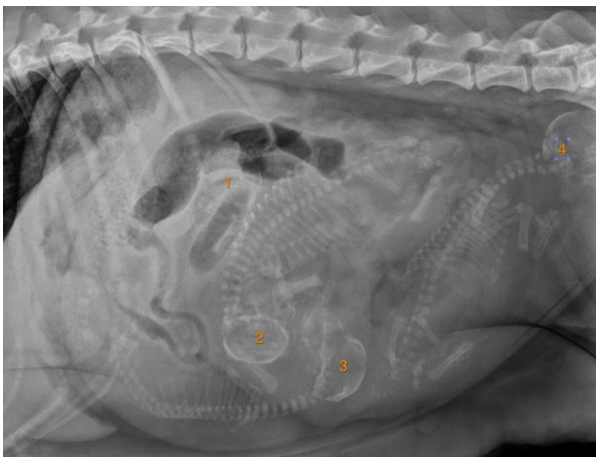


Fig.1) numbers indicate the skulls of the whelps.

Conclusions:

- 1) Gravity with 4 fully developed whelps
 - a. one with the head in the pelvic canal.
 - b. one with hindlimbs froglegged



Reported by VetCT

t. (UK) +44 (0)1223 422251 t. (Australia) +61 (0)8 9336 7632 www.vet-ct.com e. info@vet-ct.com

Co Number 6955449 Registered Office in UK St John's Innovation Centre Cowley Road Cambridge CB4 0WS UK

ABN 24601862220 Registered Office in Australia Suite 11, 185-187 High Street Fremantle WA 6160 Australia

This report is based on the available history and radiographic interpretation only and not on a physical examination of the patient. It must therefore only be interpreted by a currently licensed and registered veterinary surgeon responsible for the care of this patient.