



VETCT
CONSULTANTS IN TELEMEDICINE

IT'S YOUR CASE

Species: Equine

Breed: Andalusian horse

Sex: Gelding

Age: 3 years, 3 months

Clinical History:

Increased digital pulses and uncomfortable at the walk in all four feet. Clefing at both forelimb coronary bands

Anatomic regions: Front feet / pastern (left & right)

Details of study and technical comments: a single LM projection of each thoracic foot is provided for review. Lateral views performed one week ago are provided for comparison. Images are of good technical quality.

Diagnostic interpretation:

LEFT and RIGHT FRONT FEET:

- The dorsal border of the distal phalanx is mildly dorsally rotated relative to the dorsal border of the hoof capsule, evaluated at 4-5 degrees. This is bilaterally symmetrical
- The vertical distance between the extensor process of the distal phalanx and the coronary band is increased when compared to the previous images and currently measures 11mm (previously 5mm) in the left fore foot and 9mm (previously 6mm) in the right fore foot. A depression in the coronary band is identified bilaterally.
- The dorsal hoof is increased in thickness; the dorsal wall relative thickness to distal phalanx length is increased at 37% (published values of normal <25-27%).
- The layers of the dorsal hoof wall are indistinct, more marked in the left fore when compared to the right.
- Linear radiolucency is present within the dorsal hoof wall, between the hoof wall horn and dermal laminae.
- The sole thickness at the toe is thin bilaterally. This is reduced when compared to previous radiographs.



Reported by VetCT

t. +44 (0)1223 422251 www.vet-ct.com e. info@vet-ct.com

Co Number 6955449 Registered Office St John's Innovation Centre Cowley Road Cambridge CB4 0WS UK
ABN 24601862220 Registered Office in Australia Suite 11, 185-187 High Street Fremantle WA 6160 Australia

This report is based on the available history and radiographic interpretation only and not on a physical examination of the patient. It has been prepared specifically for interpretation by the currently licensed and registered veterinary surgeon responsible for the care of this patient.

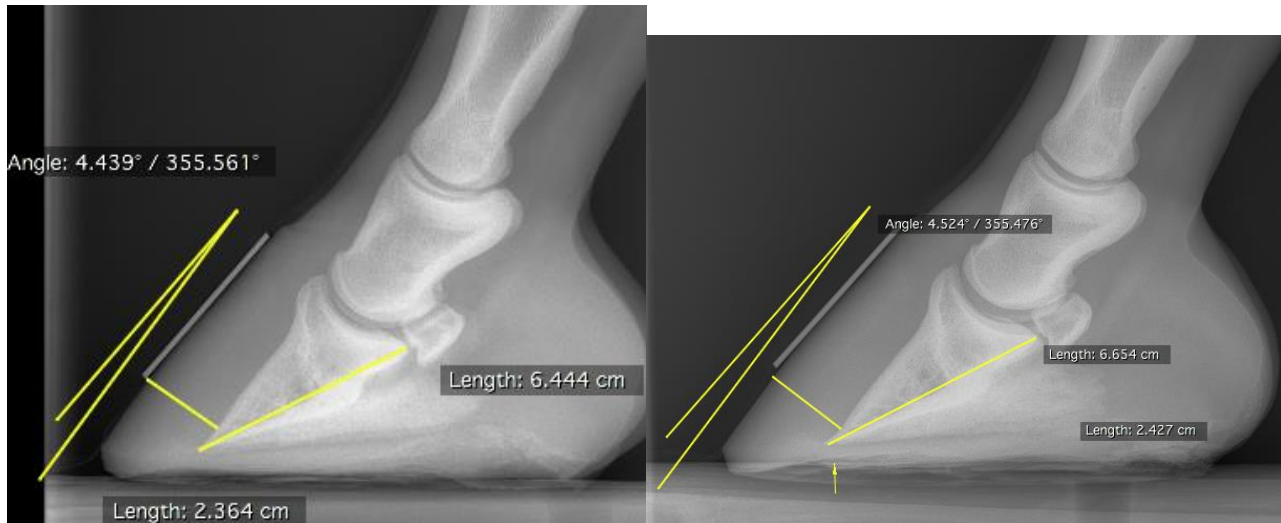


Fig 1: Progression of laminitis in the LF and RF feet.

Conclusions:

Laminitis in both front feet, with evidence of rotation and sinking of the distal phalanx.

Teaching Points:

- There are multiple radiographic signs of laminitis in this study, including:
 - Mild rotation of the distal phalanges
 - Sinking of the distal phalanx
 - Widening or thickening of the dorsal hoof wall
 - Decreased sole depth at the tip of the distal phalanx/toe
 - Coronary band halo
 - Radiolucencies within the dorsal hoof wall
- Correlation of the radiographic findings with clinical signs and physical exam is needed for evaluation of acute, chronic or acute on chronic laminitis.
- Comparison to previous radiographs is also helpful.
- If hoof trimming is performed, radiographs prior to farrier intervention is recommended.

See Chapter 3: The Foot. Butler, J. A., Colles, C. M., Dyson, S. J., Kold, S. E., & Poulos, P. W. (2017). *Clinical radiology of the horse*. John Wiley & Sons.

Sherlock, C., & Parks, A. (2013). Radiographic and radiological assessment of laminitis. *Equine Veterinary Education*, 25(10), 524-535.



Reported by VetCT

t. +44 (0)1223 422251 www.vet-ct.com e. info@vet-ct.com

Co Number 6955449 Registered Office St John's Innovation Centre Cowley Road Cambridge CB4 0WS UK
 ABN 24601862220 Registered Office in Australia Suite 11, 185-187 High Street Fremantle WA 6160 Australia

This report is based on the available history and radiographic interpretation only and not on a physical examination of the patient. It has been prepared specifically for interpretation by the currently licensed and registered veterinary surgeon responsible for the care of this patient.