

IT'S YOUR CASE

Species: Cat Breed: unknown Sex: unknown Age: Young

Clinical History: Post op and follow on SH2 fracture in a cat.

Details of study and technical comments: Orthogonal views of RH stifle region are available - post operative, then follow up study.

Diagnostic interpretation:

RIGHT HIND: In the distal femoral physis, the SH2 fracture has been reduced and fixated with implants in a crosswise fashion. The implant engage minimal metaphyseal bone (blue arrow heads). The fracture has good overall alignment, but the femoral condyles are caudally rotated at the stifle joint (grey stars). The soft tissues are thick and contain gas.

During follow up, smooth periosteal reaction is noted along the femoral diaphysis (blue arrow heads) and new bone is noted near the fracture (blue arrow). The implants are replaced with longer cross pins that now extend to the distal diaphysis of the femur. The soft tissues become thin and contain gas.

The included hip, pelvis, caudal abdomen, and tibia are normal.

Conclusions:

1. Internal fixation of RH femoral fracture, including fracture revision with longer cross pins
2. Periosteal reaction due to trauma to soft tissue, periosteal trauma during fracture repair, and/or a result of prior soft tissue infection.
3. Suggest continued radiographs to monitor fracture healing with the revised implants.

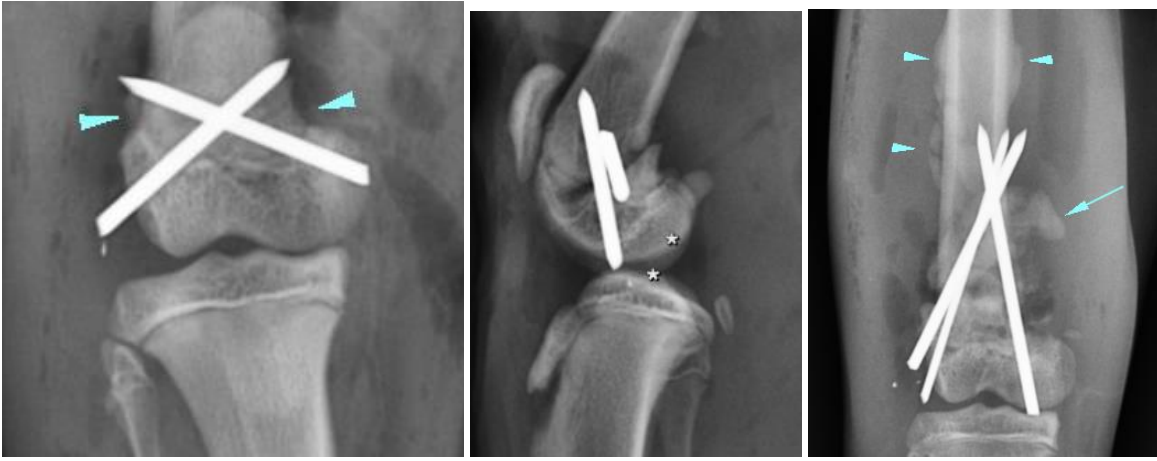


Reported by VetCT

t. +44 (0)1223 422251 www.vet-ct.com e. info@vet-ct.com

Co Number 6955449 Registered Office St John's Innovation Centre Cowley Road Cambridge CB4 0WS UK
ABN 24601862220 Registered Office in Australia Suite 11, 185-187 High Street Fremantle WA 6160 Australia

This report is based on the available history and radiographic interpretation only and not on a physical examination of the patient. It has been prepared specifically for interpretation by the currently licensed and registered veterinary surgeon responsible for the care of this patient.



Reported by VetCT

t. +44 (0)1223 422251 **www.vet-ct.com** **e.** info@vet-ct.com

Co Number 6955449 Registered Office St John's Innovation Centre Cowley Road Cambridge CB4 0WS UK
ABN 24601862220 Registered Office in Australia Suite 11, 185-187 High Street Fremantle WA 6160 Australia

This report is based on the available history and radiographic interpretation only and not on a physical examination of the patient. It has been prepared specifically for interpretation by the currently licensed and registered veterinary surgeon responsible for the care of this patient.